



PATIENT

Whittier Allman

SPECIES

Feline

BREED

DSH

SEX

Male Neutered

AGE

12 years

WEIGHT

12lbs

INTERPRETED BY

Maggie Machen
Lamy, DVM
DACVIM (Cardiology)

PRESENTING CLINICAL SIGNS

History: Presented today in respiratory distress . Grade II-III/VI systolic murmur; pleural effusion. Thoracentesis removed 250 ml transudate. Sedated with alfaxalone, butorphanol and midazolam. Whittier had an echocardiogram in September 2018 (Mandi Kleman, DVM, DACVIM-Cardiology): LA 1.28 cm; LA:Ao 1.37; IVS 0.57 cm; PW 0.57 cm; LVOT Vmax 1.42 m/s; normal LA size; mild-moderate diffuse LVH. Was normotensive. Interpretation: HCM - suspected.

ECHOCARDIOGRAM FINDINGS

2D, m-mode, color flow and Doppler imaging is available.

Left ventricle: The LV dimeter is normal with severely depressed myocardial function. The LV wall thicknesses are highly irregular with borderline septal dimension and marked free wall thinning, most consistent with an infarct. The endocardium appears remodeled. The papillary muscles are remodeled and asymmetric.

Left atrium: The left atrium and auricle are severely dilated with subtle spontaneous contrast.

Mitral valve: The mitral valve is normal in structure and mobility. No systolic anterior motion is seen. Trace mitral regurgitation.

Aortic valve/Aorta: Aortic valve is normal. Normal outflow velocity, laminar flow. No AI.

Right ventricle: Right ventricular appears mildly thickened.

Right atrium: The right atrium is moderately dilated.

Tricuspid valve: Tricuspid valve is normal with mild TR.

Pulmonic valve/Pulmonary artery: The pulmonic valve appears normal in morphology and mobility. No PI.

Pericardium/other: Scant pericardial effusion. Large volume pleural effusion. No obvious cardiac tumors.

Heart rhythm: ECG reveals a sinus rhythm with an average HR of 120bpm.

2-Dimensional Measurements

Ao diam (cm)	0.8
LA diam (cm)	2.1
LA:Ao (Swe)	2.5
IVS thickness (cm)	0.51
LVID diastole (cm)	1.7
PW thickness (cm)	0.22
LVID systole (cm)	1.46
FS (%)	14

Doppler Measurements

PV Vmax (m/s)	NM
AoV Vmax (m/s)	0.44
MR Vmax (m/s)	NA
TR Vmax (m/s)	NA
TR PG (mmHg)	NA

IMAGING

PERFORMED BY

Pamela Harrigan,
RDCS

HOSPITAL NAME

Norfolk County
Veterinary Service

REFERRING VET

Dr. Dabas

INVOICE

26888

DATE

10/13/22

INTERPRETATION OF THE FINDINGS

Hypertrophic cardiomyopathy (HCM) persists with development of burn out or end-stage pathology. This is compared to the prior study (with mild to moderate LVH). There is evidence of marked progression with an asymmetric LV appearance and thinning of the free wall, most consistent with an infarcted region. The systolic function is severely depressed and both atria are significantly dilated. These findings certainly confirm the respiratory distress is secondary to pleural effusion caused by congestive heart failure.

Even if we are able to stabilize the situation through a thoracocentesis and medical management, the mean survival time for cats at this stage of disease is 8-12 months.



PATIENT
 Whittier Allman

Patient will always be at high risk for recurrent episodes of CHF, development of blood clots, malignant arrhythmias and/or sudden death in the future.

SPECIES
 Feline

RECOMMENDATIONS

- Consider hospitalization and thoracocentesis.
- Institute Furosemide 1-2mg/kg PO q12h.
- Institute Plavix 75mg tabs; Give ¼ tab by mouth every 24 hours (NOTE: bitter along cut edge, may cause foaming at the mouth; coat in entirety).
- Institute Pimobendan 1.25mg PO q12h.
- Monitoring of sleeping breathing rates at home is recommended as the best way to screen for recurrent CHF at home.
- Avoid anesthesia, steroids and/or fluid therapy unless absolutely necessary in the future.

BREED
 DSH

SEX
 Male Neutered

AGE
 12 years

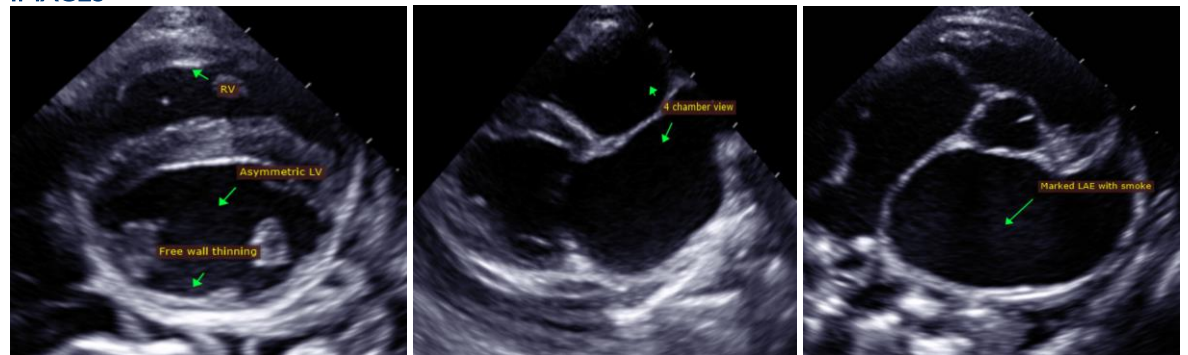
PLAN

- Monitor renal values/BP in 1-2 weeks, then every 3-4 months lifelong. If BP is >130mmHg and patient is doing well at home, consider an ACE-I 0.5mg/kg PO q12h.
- A recheck echocardiogram is recommended in 6 months to assess for progression, sooner if issues arise in the interim.

WEIGHT
 12lbs

IMAGES

INTERPRETED BY
 Maggie Machen
 Lamy, DVM
 DACVIM (Cardiology)



IMAGING PERFORMED BY
 Pamela Harrigan,
 RDCS

The information and recommendations provided are based on the images presented by the referring veterinarian. No evaluation can be communicated regarding pathology that was not visible in the image/video clips provided.

HOSPITAL NAME
 Norfolk County
 Veterinary Service

Thank you for this referral. This report was generated using transcription software, and minor dictation errors may be present. If the clinical or image interpretation does not parallel your findings or if I can be of any further assistance, please contact me.

REFERRING VET
 Dr. Dabas

Maggie Machen Lamy, DVM
 Diplomate of the American College of Veterinary Internal Medicine (Cardiology)
 info@sonopath.com

INVOICE
 26888

DATE
 10/13/22